



ORIGINAL RESEARCH PAPER

Dental Science

AMELOBLASTIC FIBRO-ODONTOMA IN A KID -AN IMPOSTOR IN RADIOGRAPHY

KEY WORDS: Ameloblastic fibro-odontoma, Odontogenic tumours, Benign jaw lesions, Benign odontogenic tumour, Odontome, Mixed odontogenic tumour

DR. PRAVEENA RAMAN

Senior Lecturer Department of Oral Medicine & Radiology Satyabama University Dental College and Hospital Chennai, Tamil Nadu, India. - Corresponding author

ABSTRACT

Ameloblastic fibro-odontoma (AFO) is a rare benign mixed odontogenic tumor derived from epithelial and ectomesenchymal elements that form the dental tissues. It occurs as an intraosseous lesion mostly, on the mandibular posterior region, generally asymptomatic and occurs more predominantly in children and in young adults with a male predominance. AFO is found on radiographic evaluation of patients with unerupted or impacted teeth in many cases with a circumscribed radiolucency, which contains radiopaque foci of various sizes and shapes. Histological examination reveals a fibrous soft tissue, islands of odontogenic epithelium, and a disordered mixture of dental tissues. Treatment of AFOs usually consists of enucleation or surgical curettage, which is possible due to their benign biological behaviour. Here, we are reporting a case of AFO in a primary school age boy.

Introduction:

Ameloblastic fibro-odontoma (AFO) is defined by the World Health Organization (WHO) as a neoplasm composed of proliferating odontogenic epithelium. It is a benign, slow-growing, expansive tumour that presents as a painless swelling in the posterior mandible or maxilla and clinically appears as a well-encapsulated, benign lesion. Histologically, AFO has been classified as an ameloblastic fibroma or odontoma. Despite numerous efforts, however, there is still a considerable confusion concerning the nature, the histology and the therapy of these lesions.^{1,2} AFO is relatively a rare tumour. Studies indicate that AFO is seen ranging from 0.3% - 1.7% of oral pathology biopsy specimens submitted as possible odontogenic tumors.^{3,4} AFO was originally termed ameloblastic odontoma before the current nomenclature. The aim of this article is to report a case of AFO in mandibular posterior region on the left side in a primary school age boy.

Case description:

A 7 year old male, reported to the department of Oral Medicine and Radiology, with a chief complaint of pain and swelling at left lower back tooth region since 3 months. Patient was apparently healthy 3 months back after which patient started eliciting dull, intermittent pain at left lower back tooth region. Pain aggravates on mastication. Pain was followed by swelling which was initially smaller in size and gradually increased to attain the present size. Pain and swelling temporarily subsided on medications and the pain is not of radiating type. Patient very frequently have the habit of applying a topical herbal balm extraorally to get relieved from pain and swelling. Patient also noted occasional pus discharge at that region. No history of recent trauma. No relevant medical history was elicited. Patient had a history of extractions at left lower back tooth region 2 years back. Patient brushes once daily and consumes vegetarian diet. No relevant family history was elicited. On, General examination, the patient is well built, well nourished, calm, conscious, cooperative, well oriented to time and space with normal gait, and no abnormal findings in vital and constitutional signs.

On extraoral examination, facial asymmetry was noted. (Fig 1) A single hemispherical shaped swelling was evident at left lower half of face approximately measuring 5cm×5cm, extending posteriorly till angle of mandible, anteriorly 3cm away from the commissure, superiorly 4cm below alaragral line and inferiorly involving and extending 3cm below left lower border of mandible. Colour and skin over the swelling appears to be normal. Inspectory findings regarding site, size, shape, number and extension are confirmed. Swelling is firm-hard in consistency, non compressible, non fluctuant and tender. Skin over the swelling is pinchable. No abnormalities were found on examining the TMJ's and the lymph nodes. Intraorally, an erythematous area was present on the left mandibular posterior alveolus area with missing 36, 37 & 38. (Fig 2) The overlying surface appeared rough. The colour varied from yellowish-black. Slough was present in the affected area. On palpation, it was tender. Pus discharge was present.

Based on the history and clinical examination, a provisional diagnosis of Chronic suppurative Osteomyelitis involving the left side of the mandible was made. A differential diagnosis of Consolidated abscess was made. Further procedures were carried out after obtaining an informed consent from the patient's parents. Haematological investigations were apparently normal. Radiographic investigations included OPG and CBCT.

OPG revealed a single well defined circular mixed density lesion with radiopaque predominance roughly measuring 2cm×2cm at left posterior mandible within the bone in the mandibular second and third molar region. (Fig 3) The cortical borders are well defined and regular. Immediately adjacent and surrounding to the cortical border is a radiolucent capsule. The content of the lesion is largely radiopaque with irregular mass of calcified tissue. Mild erosion of lower border of mandible was also noted. Inferior alveolar canal was unable to be traced. Other dental findings revealed, Impacted 36, missing^{37,38} and endodontically treated³⁴ and³⁵.

CBCT (Fig 4) revealed a single well defined lesion with radiopaque predominance measuring approximately 20.9 mm×23.1 [Fig 4 (a) i] mm in the molar region of left posterior mandible associated with an impacted 36 extending anteriorly upto the follicle of impacted 36 and posteriorly upto the junction of molar-ramus region, superiorly upto the superior border of mandible and inferiorly about 1mm above the inferior border of mandible obscuring the mandibular canal causing expansion of the buccal and lingual cortical plates. A small discontinuity [Fig 4 (a) ii] of about 1mm width in the superior border of mandible in the anterior border of the lesion just above the cusp of impacted 36 was noted. Erosion of lower border of mandible beneath the lesion, was also noted. [Fig 4 (a) iii] Radiographic differential diagnosis included, Complex odontoma, Ameloblastic fibro-odontoma, Cemento-ossifying fibroma and Periapical cemental dysplasia.

Histopathological examination (Fig 5) showed odontogenic epithelium in the form of islands, strands and cords in a loose connective stroma. with mature tubular dentine interspersed with empty areas (must have contained enamel which was removed during decalcification), areas made of loosely arranged collagen fibres with fibroblast resembling pulp, and a thin layer of cementum at the periphery, suggestive of Ameloblastic Fibro-odontoma.

Surgically, (Fig 6) under GA, patient intubated, draped and painted with 2% Lignocaine with adrenaline 1:80,000 administered in buccal vestibule from³³⁻³⁸ region. Crevicular incision placed from 33-35 region and crestal incision placed from³³⁻³⁸ region. Mucoperiosteal flap was raised. Lesion and impacted 36 was visualised. Impacted 36 was removed by splitting and the lesion was removed in pieces with preservation of mental nerve and inferior alveolar nerve. Lower border of mandible intact. Adequate saline irrigation was done using 3'-0 vicryl. Gauze soaked in betadine and placed intraorally.

Pressure bandage was given extraorally in the left side angle region. Patient was extubated. (Fig 7,8,9) Recovery uneventful.

Discussion

The histogenesis of AFO is controversial. It is a benign tumour that exhibits the same benign biologic behaviour as that of ameloblastic fibroma, showing inductive changes that lead to the formation of both dentin and enamel (5). This is in contrast to the ameloblastoma. Conversely, the term “odontoameloblastoma” (or “ameloblastic odontoma”) refers to tumors representing a histological combination of ameloblastoma and complex odontoma, which behave in the invasive manner of classic ameloblastoma (6). According to the revised World Health Organization (WHO) classification (7), ameloblastic fibroma and AFO are believed to be stages of complex odontoma formation (5). This means that the aforementioned lesions should not be considered as distinct entities.

Cahn and Blum (8) postulated that ameloblastic fibroma (the histologically least differentiated tumor) develops first into a moderately differentiated form, following AFO and eventually into a complex odontoma. However, the concept that these lesions represent a continuum of differentiation is not widely accepted, with other researchers suggesting that they are separate pathologic entities (9). In some studies, the term AFO represents a histological combination of ameloblastic fibroma and complex odontoma (9). The majority now agrees that AFO exists as a distinct entity, but it can be histologically indistinguishable from immature complex odontoma. The arrangement of the soft tissues and the development stage of the involved tooth are useful criteria for diagnosis. Despite numerous efforts, however, there is still considerable confusion concerning the nature of these lesions. AFO is relatively rare, with the prevalence among oral biopsies being about 1% (9).

This lesion usually occurs in people less than 20 years old (mean age of 11), and age is thus an important characteristic in the differential diagnosis. This lesion is usually found in the molar area (6). AFO is mainly found in posterior mandible with male to female ratio as 6:1 (10), and it occurs exclusively as an intraosseous tumour, which is also the same in our case. The histological features of ameloblastic fibroma (AF) include odontogenic ectomesenchyme that resemble the dental papilla and strands or islands of odontogenic epithelium. If there is dentin formation, the lesion should be diagnosed as ameloblastic fibro dentinoma (AFD), whereas a lesion similar to ameloblastic fibroma showing inductive changes that lead to the formation of dentin and enamel, both is diagnosed as AFO. (11)

The two most common presenting complaints are swelling and failure of tooth eruption. (12) The case presented in this report was a 7 year old male patient with location of lesion in the posterior mandible. Mix of radiopaque to radiolucent areas differs from one lesion to another, sometimes the mineralized elements in the tumor predominate and the lesion may be radiographically similar to a odontoma. The case presented in this report had a radiopaque mass surrounded by thin radiolucent zone resembling an odontoma or WHO type II calcifying odontogenic cyst but on histopathology proved to be ameloblastic fibro odontoma. In the present case in spite of large radiopaque mass, proliferation of ectomesenchymal component containing islands of odontogenic epithelium along with dental tissue was observed. Hillmann and his colleagues observed that AFO bear great resemblance to common odontomas and suggested, all odontomas to be sent for microscopic examination. (13)

Many authors reported that AFO can be managed through a surgical curettage without removal of the adjacent teeth (5,9,14). As noted in the literature, not all lesions previously classified as AFO are, in fact, aggressive lesions. If there is a recurrence accompanied by a change of the histological pattern toward a more unorganized fibrous stroma with displacement of the epithelial component, then more extensive treatment procedures appear to be indicated (15). Determination of a case-dependent treatment plan may provide an optimum outcome. Long-term

follow up with short intervals should be maintained in the management of AFO. In our case, no recurrence was observed two years after the surgery.

To conclude, AFO is a rare benign odontogenic tumor found predominantly in a younger age group. Dental practitioners should be aware that AFO can occur with impacted or missing tooth in maxilla or mandible, irrespective of small to large mass. Histopathologic study is needed to exclude other mixed odontogenic tumors in the jaw before reaching a confirmatory diagnosis so that an early diagnosis with prompt treatment can prevent complications.

Photographs

Fig 1- Extraoral view- Evidence of facial asymmetry due to a diffuse swelling at left side, posterior mandibular region.

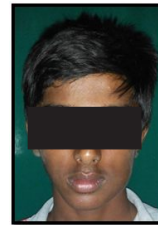

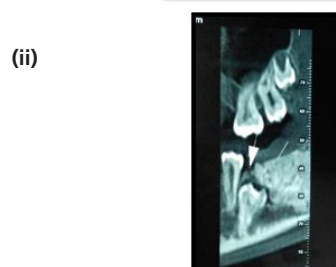
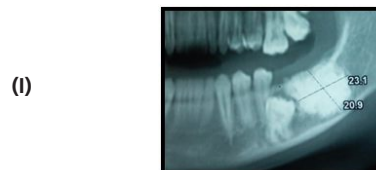
Fig 2- Intraoral view- Missing 36, 37 & 38 with yellowish-black slough at the region of 37.

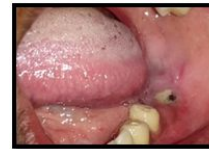

Fig 3- Panoramic view- Evidence of a single well defined roughly measuring 2cmx2cm circular mixed density lesion with radiopaque predominance at left posterior mandible within the bone in the mandibular second and third molar region with well defined and regular cortical border surrounded by a radiolucent capsule.

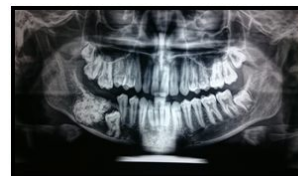

Fig 4 (a) CBCT coronal view- (i) Evidence of a single well defined lesion with radiopaque predominance measuring approximately 20.9 mmx23.1 mm in the molar region of left posterior mandible associated with an impacted 36. (ii) A small discontinuity of about 1mm width in the superior border of mandible in the anterior border of the lesion just above the cusp of impacted 36 was noted. (iii) Erosion of lower border of mandible beneath the lesion, was also noted.



(iii)

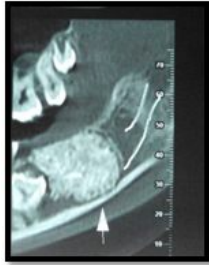

Fig 4 (b) CBCT axial view- Bucco-Lingual expansion of the lesion in the transverse plane.

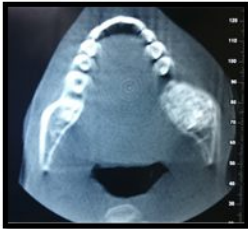


Fig 4 (c) - 3D reconstructed sagittal view- Mixed density lesion in the Antero-posterior plane

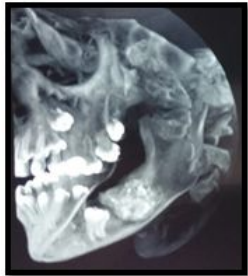


Fig 5- Pictomicrograph view- Odontogenic epithelium in the form of islands, strands and cords in a loose connective stroma. with mature tubular dentine interspersed with empty areas. Areas made of loosely arranged collagen fibres with fibroblast resembling pulp, and a thin layer of cementum at the periphery.

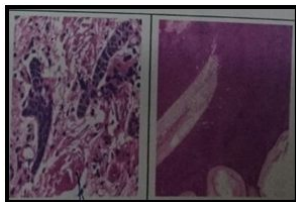


Fig 6- IntraOP- Lesion removed in pieces along with 36.

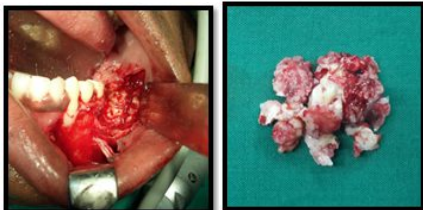

Fig 7- Immediate Post OP panoramic view

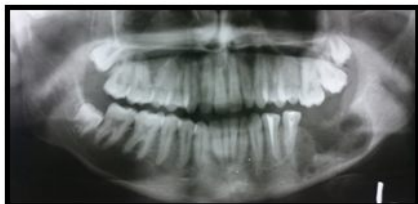

Fig 8- 10 days post OP intraoral view- No wound gaping was noted.

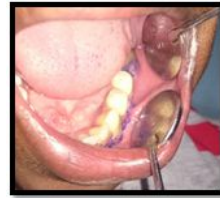
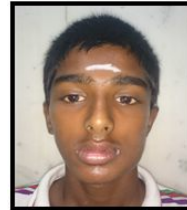
Fig 9- Extraoral view after 2 weeks- No post OP complications. Recovery uneventful.



REFERENCES

1. Giacomo De Riu et al. Ameloblastic fibro-odontoma. Case report and review of the literature. *Journal of Cranio-Maxillo-Facial Surgery*.2010;38(2):141-144
2. Helder Antonio Rebelo Pontes et al. Report of four cases of Ameloblastic fibro-odontoma in mandible and discussion of the literature about the treatment. *Journal of Cranio-Maxillo-Facial Surgery*.2012;40(2):e59-e63
3. Buchner A, Kaffe I, Vered M. Clinical and radiological profile of ameloblastic fibro-odontoma: An update on an uncommon odontogenic tumor based on a critical analysis of 114 cases. *Head Neck Pathol* 2013;7:54-63.
4. Gantala R, Gotoor SG, Kumar RV, Munisekhar MS. Ameloblastic fibro-odontoma. *BMJ Case Rep* 2015;2015. pii: Bcr2015209739.
5. J. E. Hamner III and M. E. Pizer, "Ameloblastic odontoma. Report of two cases," *American Journal of Diseases of Children*.1968;115(3):332-336.
6. S. P. Hooker, "Ameloblastic odontoma: an analysis of 26 cases," *Journal of Oral Surgery*.1967;24:375-376.
7. Y. Takeda and C. E. Tomich, "Ameloblastic fibro-odontoma," in *World Health Organization Classification of Tumors (WHO)—International Agency for Research on Cancer (IARC)*, IARC Press, Lyon, France, 2005.
8. L. R. Cahn and T. Blum, "Ameloblastic odontoma: case report critically analyzed," *Journal of Oral Surgery*.1952;10:169-170.
9. F. V. O'Brien, "Ameloblastic odontome. A case report," *British Dental Journal*, vol. 131, no. 2, pp. 71-72, 1971.
10. Guerrisi M, Piloni MJ, Keszler A. Odontogenic tumors in children and adolescents. A 15-year retrospective study in Argentina. *Med Oral Patol Oral Cir Bucal* 2007;12:E180-5.
11. Barnes L, Eveson J, Reichart P, Sidransky D. *World Health Organization classification of tumours. Pathology and genetics head and neck tumours*. Lyon: IARC Press; 2005. p. 284-5.
12. Anneroth G, Modéer T, Twetman S. Ameloblastic fibro-odontoma in the maxillae. A case report. *Int J Oral Surg* 1982;11:130-4.
13. Hillmann G, Donath K. Clinical course, histology and prognostic assessment of odontomas. *Dtsch Zahnarzti Z* 1991;46:68-70.
14. M. Okura, H. Nakahara, and T. Matsuya, "Treatment of ameloblastic fibro-odontoma without removal of the associated impacted permanent tooth: report of cases," *Journal of Oral and Maxillofacial Surgery*, vol. 50, no. 10, pp. 1094-1097, 1992.
15. A. A. Oghli, I. Scuto, C. Ziegler, C. Flechtenmacher, and C. Hofele, "A large ameloblastic fibro-odontoma of the right mandible," *Medicina Oral, Patologia Oral y Cirugia Bucal*, vol. 12, no. 1, pp. E34-E37, 2007.